# Non-Invasive Ultrasonographic Diagnosis of Peripheral Arterial Diseases

FAUSTO PASSARIELLO

*From the Centro Diagnostico Aquarius, Napoli, Italy*

**The extra-cranial carotid circulation presents some anatomical retrieving points which are useful to orient the diagnostic examination and to localise vascular lesions. Carotid stenosis could be quantified by measuring the residual diameter of the vessel and the normal one. The latter could be measured downstream from the stenosis, in the bulb, (NASCET) or estimated at the level of the stenosis (ECST). The difficult identification of early TC signs of cerebral ischaemia and the existence instead of earlier observable affections by ecography, reserves a space also for this examination in emergency, for the diagnosis of subplaque haemorrhage, internal carotid thrombosis, dissection and pre-occlusive stenosis. The vascular surgeon could take advantage from an echo examination, that allows him to evaluate in advance the arteriotomy extension, the search for the plane of cleavage, the extension of the aterosclerotic plaque and the circulatory cerebral compensation. Ecotomography is furthermore useful in the study of the already operated patient, which often presents an upset of the normal anatomy. Doppler indexes can help in the assessment of the diagnosis of cerebral vascular diseases. Some of them have only a historical value today, but it is useful to review the most important ones: Carotid ratio, the Resistance index, spectral analysis indexes, Gosling Index. Winsor Index and the segmental pressure gradient are the most common lower limbs indexes. Echotomographic and Doppler examination of the arterial circulation requires a notable skill. That is why the ecographic operators should spend a period of theoretical and practical learning and of assisted diagnostic and reporting experience, before they could be considered completely reliable.**

**KEY WORDS**: Ultrasounds - Arteries - Surgery - Diagnosis

Presented at Vascular Seminars of the Ideal Society of Vascular Biomechanics (ISVB), March 27 - June 13 1998, Caserta, Italy.

Address reprint requests to: Dr Fausto Passariello, Via Cilea, 80127 Napoli, Italy.

Ecography and Doppler investigation are instruments of undisputed utility in the assessment of arterial circulation.

Ecographic morphological investigation is generally requested to identify the anatomical structures, to point to the site of a vascular lesion as well to evaluate its ecogenic/structural characteristics (fibrous or calcified plaque, sub-plaque haemorrhage) or to describe fairly characteristic pathological pictures (dissection, aneurysm, kinking, fibrodisplasia).[4]

## Technical Elements

Sagittal, axial and coronal terms refer to sections oriented according to the planes of the normal anatomy. Longitudinal and transversal terms, instead, refer to the direction of the vessel, although the longitudinal term tells virtually nothing regarding the angle of the section, which can generally be deduced from the position respect to the cutaneous plane. For the oblique sections, the direction must be specified case by case. In vascular Ecography they have no meaning the terms short axis or long axis, frequently used in cardiology.

As to Doppler acquisitions, they can be effected with continuous (C.W.) or pulsed (P.W.) Doppler, to choice of the operator, with the exception of the ophthalmic acquisition, that requires necessarily the use of a C.W. Doppler. The use of the colour adds simple legible information on the structures in movement, but it does not replace greyscale observation. However, it sometimes makes more difficult the recognition of the anatomical static structures, owing to overlapping artefacts.

Ultrasound penetration is conditioned by tissue echogenicity. In the abdomen the visibility is made difficult by the intestinal gas, but it can be improved by taking care of the hydration and of the absorption of the intestinal gas.

The consumption of 2 litres of water a day or of various drugs, i.e. Simeticone, with the dose of 240 mg (six 40 mg


Fig. 1. - Bifurcation of the brachio-cephalic Trunk (tbc) into right subclavian (sd) and right common carotid arteries (ccd). You can see the aorta and the right vertebral ostium (vd). There is a plaque at the origin of the subclavian.

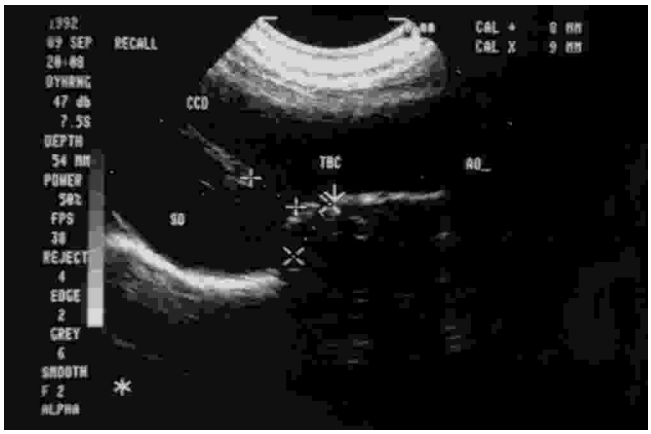


Fig. 2. - Origin from the aorta and bifurcation of the brachio-cephalic trunk (tbc) into right subclavian (sd) and right common carotid arteries (ccd). Plaque at the origin of the subclavian.

tablets) a day for 3-4 days, generally achieve the purpose. The consumption of oligo-mineral water with diuretic action could worsen the hydration. Fresh water, if usable depending on its organolectic characters, generally fits the case better.

Hydration is contra-indicated in some patients, i.e. in cardiac patients with risk of an episode of heart-failure.

The preparation of the patients is of course not practicable in emergency, but also in this case the presence of liquid in the stomach (simply a glass of water) or of urine in bladder could improve the visualisation of epigastric and hypogastric vessels respectively.

Distantiators are useful to visualise very superficial structures, as they shift the target of the observation in the focal zone of the probe. There exist several kinds of these devices, generally available from the same manufacturing companies of the ecographic devices, but it is possible to construct them also by hand, involving low expenses and achieving nearly always the same results.

## Sovraortic Trunks (TSA)

*Standard TSA examination -*

The standard examination of sovraortic trunks requires at least the following ecographic acquisitions:[20]

- Brachiocephalic Trunk
- Subclavian in transversal section with visualisation of the vertebral, bilaterally.
- Carotid Bifurcation in transversal section, bilaterally.
- Carotid Bifurcation in longitudinal section, or at least the prolongation of the Common Carotid into the Internal Carotid, bilaterally.

Besides, the following Doppler acquisitions must be added, all on both sides:

- Subclavian
- Common Carotid
- Ophthalmic
- Internal Carotid
- External Carotid
- Vertebral at the ostium
- Vertebral at the Tillaux triangle

Finally, the compressive manoeuvres for the patency of the Communicating Anterior and Posterior Arteries.[8, 9]

The examination of patients could be gone into deeper using the Transcranial Doppler, which however will not be outlined in this paper.

*TSA Origin*

The observation of the origin of the sovraortic trunks from the aorta is achieved by directing the probe at the base of the neck downwards and backwards. The probe must have a small extremity so to wedge into the angle between the neck and the clavicle.[13] Sagittal, axial and especially oblique sections, are useful in the visualisation of the Subclavian ostium.

Depending on the neck conformation, it is often possible in the longilinear subject to visualise also the aortic arc.(Fig. 1) It is also quite usual to observe a plaque of notable dimensions at the passage between the brachiocephalic trunk and the Subclavian artery. (Fig. 2) It is, however, an alteration which often is not haemodynamically or at least not clinically significant, considering the wide calibre of the vessels at this level.

In TSA examination the integrity of the pre-vertebral Subclavian segment is of great importance, due to well known possible haemodynamic consequences (steals). Post-vertebral pathology instead has consequences only to the haemodynamics of the upper limb. The distinction is fundamental and must always be reported.

*Vertebral Artery*

The observation of the vertebral artery is possible at the ostium as in transversal (Fig. 3) as in longitudinal (Fig. 4) section of the subclavian, while in its inter-transverse


Fig. 3. -Transversal section of the right subclavian (sd) with visualization of the vertebral in longitudinal section. The cursors delimit the vertebral ostium.

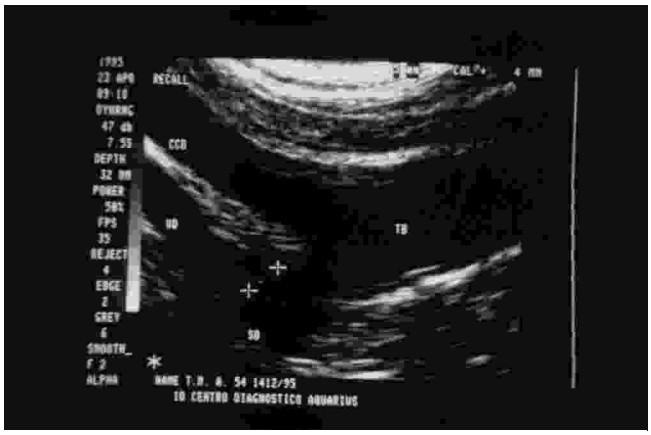


Fig. 4. - Bifurcation of the brachio-cephalic trunk into right subclavian (sd) and right common carotid arteries (ccd) in longitudinal section with visualization of the vertebral (vd) in longitudinal section. The image is accidental because not always the vessels are in the same plane. The cursors delimit a plaque (hardly visible) at the origin of the vertebral.

apophyses path, the arterial vertebral trunk is visible between the shades of the transverse apophyses of the cervical vertebrae.

*Extracranial Carotids*

The extra-cranial carotid circulation presents some anatomical points that could be easily pointed out as a help to orientate the diagnostic examination (retrieving points). They are:

- The inferior thyroid artery that crosses the common carotid artery at the base of the neck. (Fig. 5)
- The superior thyroid artery that originates from the external carotid artery, therefore making simpler its differentiation from the internal carotid artery. (Fig. 6)
- The thyroid-lingual-facialis venous trunk, that crosses over the common carotid artery to join into the internal jugular vein. (Fig. 7) Together with the internal jugular vein it forms the venous plane. In carotid surgery the ligature and the section of the venous trunk permits the retraction of the internal jugular vein and the retrieval of the common carotid axis. The venous trunk is generally caudal to carotid bifurcation.
- The internal and external jugular veins, of which the first is at narrow contact with the common carotid artery.
- The sternum-cleidomastoid muscles, the long muscle of the neck, the anterior scalene (Fig. 8), the posterior part of the digastric muscle and the omohyoid muscle.

*Suspicious Shades*

When tissue composition causes iper-reflectivity, ultrasounds cannot visualise the deep structures, thus determining an iper-ecogenic region with the phenomenon of the posterior acoustic shade (shade cone). In order to distinguish the shade cone from an artefact, it is sufficient to consider the direction of the ecographic projection. Using sector or conic probes the shades have a radial projection, while using linear ones they look like rectangular strips.

Iper-reflecting plaques on opposite walls of the vessel are an important example. In such a case, a shade could hide an important pathology of the opposite wall or an important intravessel development of the plaque, which is on the same vessel wall. (Fig. 9)

Sometimes, in the neck, it is possible to observe the vessel from the opposite part. This way one achieves the inversion of the shade direction, that therefore will hide deep structures behind (according to the ecographic projection) the iper-reflecting zone, but will show instead the internal vessel structure, which was not visible in the opposite projection. (Fig. 10)

In the transverse section two radial shades of no pathological significance (similar to moustaches) are detectable, caused by the increased reflectivity of the lateral vessel walls in shear projection as compared to anterior and posterior walls.

The effect is a good visibility of the anterior and posterior walls, while lateral ones are masked. That is why it is necessary to proceed to several observations according to different points of view, in order to observe the transverse section in its entirety.

Another source of error is constituted by the iper-reflecting image of the hyoid bone, which often is next to the bifurcation and causes a clear acoustic shade, simulating a calcified structure. Distinction is easy by means of deglutition, which moves the image, leaving almost unchanged, instead, the position of the vessels.

*Search for Proper Echografic Projections*

The observation of the bifurcation in a longitudinal section is a fortunate exception and is not always the rule, in since not always the three tripod vessels are in the same plane. On the other hand, an observation of all the three

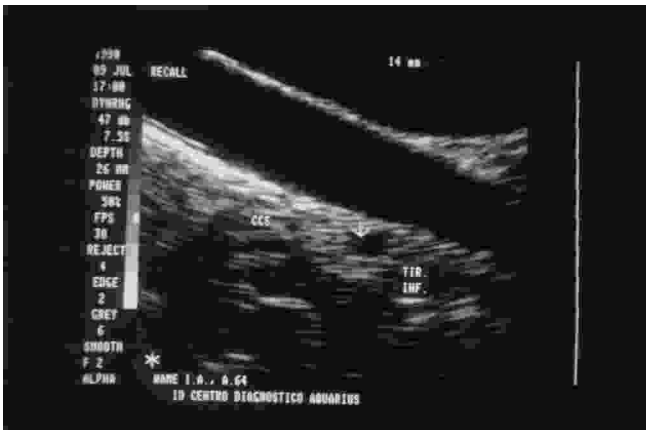


Fig. 5. - Left common carotid artery (ccs) in longitudinal section at the base of the neck and inferior thyroid (tir.inf.) in transversal section. Intimal thickness of the posterior wall of the common carotid artery.

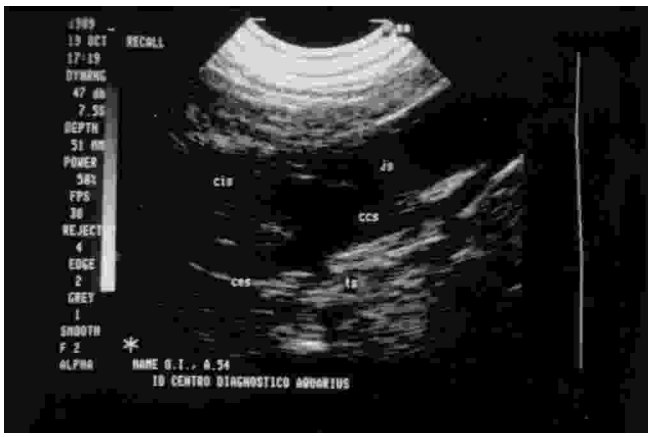


Fig. 6. - Longitudinal section of the left carotid bifurcation and visualization of the common (ccs), internal (cis) and external (ces) carotids and of the origin of the superior thyroid (ts). Above the left jugular vein is visible. (js)

vessels in a single longitudinal section is possible (only a short segment in the same plane). This can happen only if the plane of the section is accessible and not next to the trachea or to the spine, which are structures that frustrate every ecographic observation.

In these cases, the only possible and correct observation is the prolongation of the common carotid into the internal carotid (Fig. 11), which effectvely constitutes the standard longitudinal projection of the bifurcation.

As regards the diagnostic goals, however, the most reliable projection of the bifurcation is the transverse one. (Fig. 12)

*Stenosis Percentage Computation*

Carotid stenosis can be quantified by the formula:

$$\% \text{ Stenosis (in diameter)} = (1-S/N) \times 100 = T/N \times 100$$

where S is the residual diameter of the vessel and N is the normal one. The latter can be measured downstream the stenosis, in the bulb, (NASCET) (16) or estimated at the level of the stenosis (ECST),[7] in the latter case more easily by ecography rather than by angiography.

In ecographic longitudinal section of the bifurcation, both the methods can be used, while a single transverse section in the point of greater stenosis allows only the ECST measure, while two transverse sections are required for the NASCET measure.

As an alternative, in place of the residual diameter, the endoluminal projection T of the plaque could be measured, but the latter measure presupposes the not always verified possibility of identifying the vessel walls also in the site of the lesion.

The quite commonly diffused method for the calculation of the percentage of stenosis from velocity measures corresponds to that of NASCET method. In fact, at the level of the stenosis only a single velocity value ($V_S$) could be of course measured, while the other value ($V_N$) could be sampled only up or downstream to the stenosis. The percentage, however, refers to the areas rather than to the diameter.

In fact, from the relationships:

$$\text{Area} = \pi D^2/4 \;;$$

$$V = \text{Kost} \times F \;;$$

$$\text{Flow} = A_S V_S = A_N V_N \;;$$

$$A_S/A_N = V_N/V_S = F_N/F_S \;;$$

it follows easily that one can thus calculate:

$$\% \text{ Stenosis in area} =$$

$$= (1-A_S/A_N) \times 100 = (1-S^2/N^2) \times 100 =$$

$$= (1-V_N/V_S) \times 100 = (1-F_N/F_S) \times 100 \;;$$

where the adopted symbols are: D diameter, S residual diameter, N normal diameter, A area, V speed, F mean frequency in spectral analysis. They preserve their meaning also if present as a subscript.

*TSA Examination In Emergency*

The relief of central neurological signs in emergency cases imposes a diagnosis at a deeper level by TC examination of the skull. The importance of this indication has been confirmed by the vast new information that the TC examination has added to the neurological diagnostics in emergency, and besides by the possibility of identifying non

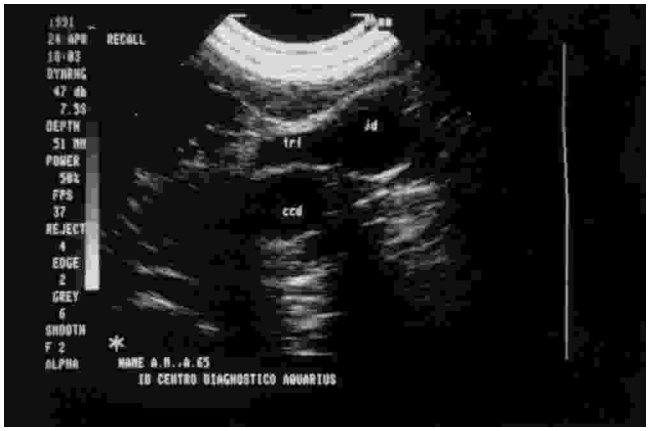


Fig. 7. - The thyroid-lingual-facial venous trunk (trf) crosses over the right common carotid artery (ccd) to join the right jugular vein. (jd)


Fig. 8. - Low transversal section at right of the neck region. You can see: the right thyroid lobe, the right common carotid artery (ccdx), the right jugular vein (vjid), the inferior thyroid artery (a.tir.inf.) in longitudinal section, the long muscle of the neck and the anterior scalene muscle.


Fig. 9. - Prolongation of the left common carotid artery (ccs) into the internal (cis). Calcified plaque of the anterior wall, that masks with its shade the vessel content and the posterior wall.

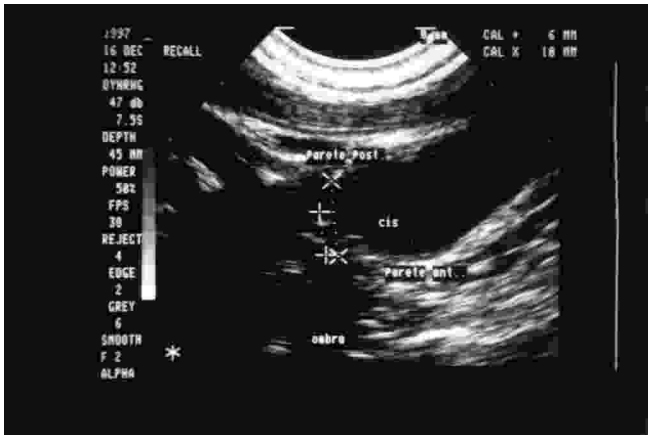


Fig. 10. - Same carotid of fig. 9, but in diametrically opposite projection. The anterior wall is now in depth and masks with its shade structures already observed in the first projection. It's instead possible to observe the lumen and superficially the posterior wall, which show a 60% in diameter important stenosis, not visible in the first projection. It is not always possible to get different projections of a same vessel. In several patients, the proximity with the thyroid cartilage and with the vertebral bones frustrates the attempt of getting other projections.

vascular affections, i.e. the tumours and the atrophies, which can simulate the ischemic or haemorragic ictus.

Nevertheless, the difficult identification of the early TC signs of cerebral ischemia and the existence instead of easily and earlier observable affections by ecography, reserves a space also for this examination in emergency.

The attention of the examiner must be focused then on the search of the following diseases:

- subplaque haemorrhage
- Internal carotid thrombosis
- Internal carotid dissection
- Internal carotid pre-occlusive stenosis.

Besides, the juvenile stroke (< 45 years), in absence of cardiac pathology, imposes the search for the ecocontrast and for the patency of the oval foramen (PFO), which can be performed by Cardiac TransEsofageal Ecography (TEE).[6] In case of positive results of the latter examination, the embolic source must be searched for.

Cerebral micro-emboli monitoring can be performed also by Transcranial Doppler.

*Echotomographic Reliefs of Surgical Interest*

As regards solely lesions due to undergo surgical treatment by tromboendoarteriectomy (T.E.A.), ecotomography can provide further anatomical information in order to foresee the peculiarities of the operative field and to guide the

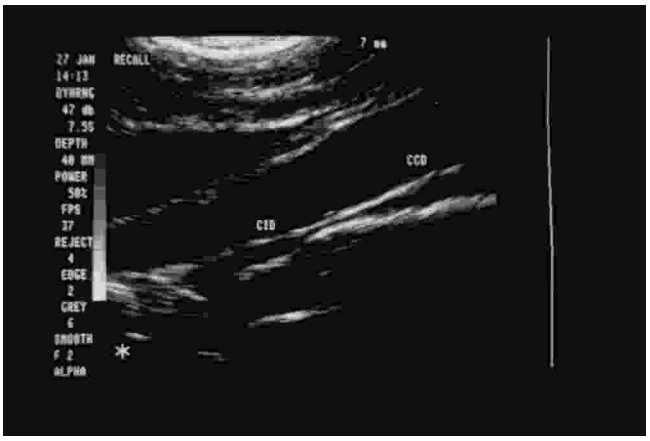


Fig. 11. - Standard Projection of the right carotid bifurcation in longitudinal section, consisting of the prolongation of the right common carotid artery (ccd) into the internal (cid).

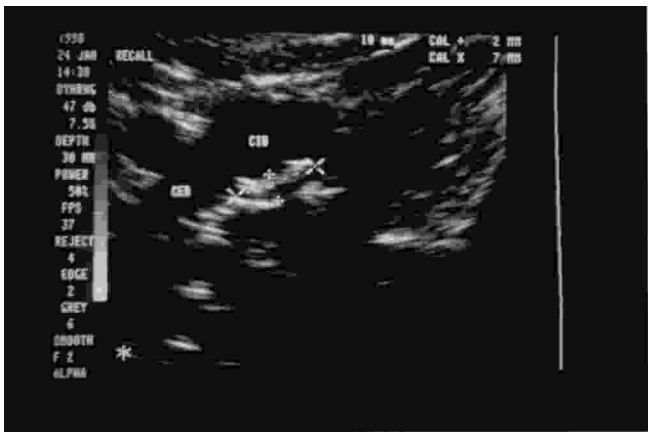


Fig. 12. - Transversal section of the right carotid bifurcation, with visualization of the internal (cid) and external (ced) carotids. There is a plaque with a 7 mm base and a 2 mm endoluminale projection.

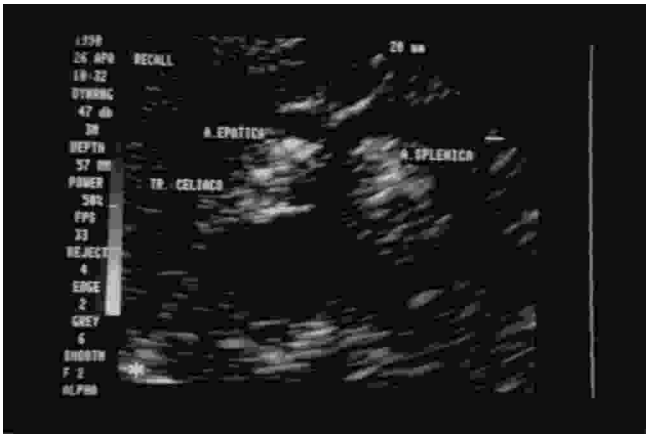


Fig. 13. - Origin from the aorta of the celiac trunk and its bifurcation into hepatic and spleen arteries. The left gastric artery is not visible.

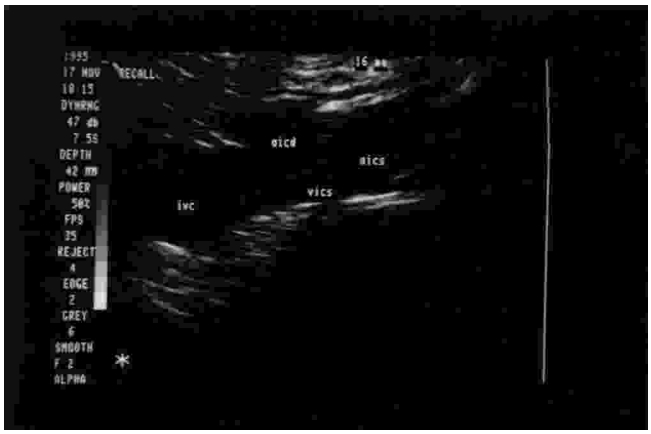


Fig. 14. -The bifurcation of the aorta with the two iliac arteries, the right (aicd) and left (aics) ones and the confluence into the inferior Cava vein (ivc) of the left common iliac vein (vics). Sometimes the latter could be squeezed by the right common iliac artery, so giving the Cockett syndrome or low nutcracker of Coolsaet.

surgeon as to possible operational difficulties.

The vascular surgeon could then take advantage from an echo examination, that would allow him to effect a preoperative choice or in anyway to appraise the following technical problems in advance:

- Arteriotomy could be longitudinal and long, longitudinal and short up to the middle of the bulb or still a transverse one.
- The search for the plane of cleavage could begin from the superior part of the plaque, from its inferior part or from the carotid bulb.
- The plane of cleavage must be positioned in the external layer of the tunica media. If there are calcifications, T.E.A. could be sometimes impracticable. The extension of the T.E.A. could englobe the common Carotid up to the internal and external ones or could interest only the internal Carotid.

The extension of the aterosclerotic plaque must be quantified as in longitudinal as in transverse section. The limits could be pointed relatively to the already described ecographic retrievals and to the position of the bifurcation. The latter besides could be located on the cutaneous piano

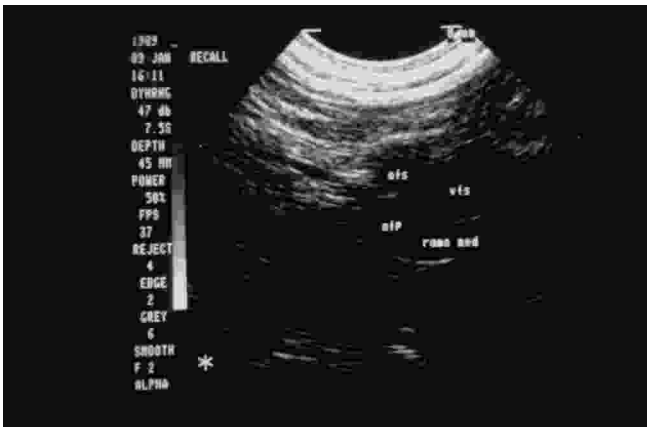


Fig. 15. -Femoral bifurcation in transversal section with visualization of the superficial (afs) and deep (afp) femoral arteries, of a medial branch of the latter and of the superficial femoral vein (vfs).


Fig. 16. - Obstruction of the right superficial femoral artery (fsd) at the middle third of thigh and its acoustic shade. By the dynamic examination a movement ahead and back of the artery is seen as a water hammer.

as to the mastoid process and to the jugular notch.

These indications help facilitate the location of the surgical section and help the surgeon in making the best choice of the type of arteriotomy. The involvement of the internal carotid beyond the limit of the posterior part of the digastric muscle or the involvement of the external Carotid suggest a long arteriotomy up to the bulb, and the extension of the skin section up to the mastoid process, as well as the execution of an angioplasty.

The thickness of the arterial wall is generally not appraisable for the isoechogenicity of the surrounding tissues. Nevertheless, if possible, the extension of a plaque in the vessel wall must be reported (different echogenicity and not regularity of the contour), especially for the calcified plaques, that could render practically not feasible the search for the piano of cleavage of the T.E.A.

Most of the here-outlined information, and detectable by ecotomography, is clearly visible (or palpable) on the operating-table. The utility of their acquaintance can consist in the planning of the intervention by the surgeon. The use of the ecotomography in the study of the already operated patient, which often presents an upset of the normal anatomy, must not be understimated

Last of all, the surgeon has an interest in doppler evaluation of the circulatory cerebral compensation (patency of the anterior and posterior communicating arteries of the circle of Willis), in order to execute a carotid clampage. [8,9,10]

*Diagnostic Indexes*

Doppler indexes can help in the assessment of the diagnosis of cerebral vascular diseases. Some of them have a merely historical value today, but it is useful to review the most important ones.

Carotid ratio (R.C.)[8] is adimensional and is computed from diastolic velocities in the internal (DI) and in the common carotid artery (DC):

$$R.C. = DI/DC;$$

It looks like the reciprocal of the area percent stenosis index, computed by NASCET method and normally ranges from 1 to 1.5.

Pressure/Perfusion index (I.P.P.),[8] measured in mmHg/(cm/sec.), analogous of the resistance index, is related to the diastolic part of the heart cycle, and takes into account the value of the diastolic brachial arterial pressure (D.O.A.P. in mmHg):

$$I.P.P. = D.O.A.P. / (DC +1) ;$$

I.P.P. ranges 2-5 before 40 years, 3-6 from 40 to 60 years, 4-8 over 60 years, at rest and supine position.

The carotid extensibility index (I.D.C.)[8] is a measure of the compliance of arterial walls and introduces also the value of the systolic brachial arterial pressure (S.O.A.P.), but all pressure values are measured in cmHg, so that I.D.C. is measured in ( cm/sec.) / cmHg:

$$I.D.C. = (A – D) / (S.O.A.P. – D.O.A.P.)$$

I.D.C. ranges 20-10 before 40 years, 20-8 from 40 to 60 years, 8-4 over 60 years.

The most-used index is the Resistance index (I.R.), [21] an adimensional value computed from the systolic (A) and diastolic (D) velocities in the common carotid artery, nor-

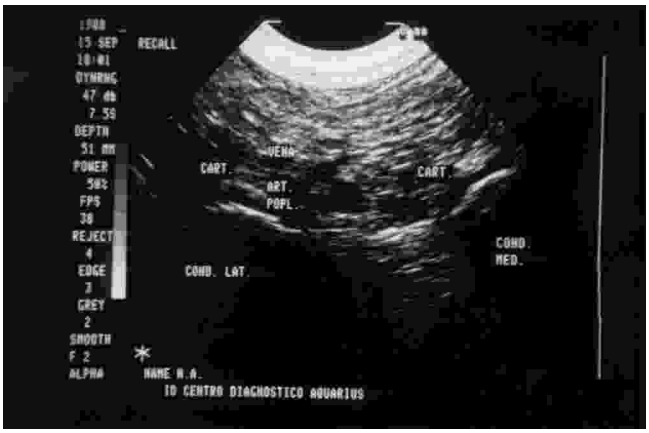


Fig. 17. - Transversal section of the popliteal hollow with visualization of the popliteal artery (art. popl.) and of the vein, of the cartilages (cart) and of the lateral and medial femoral condyles (cond. lat. and cond. med.)

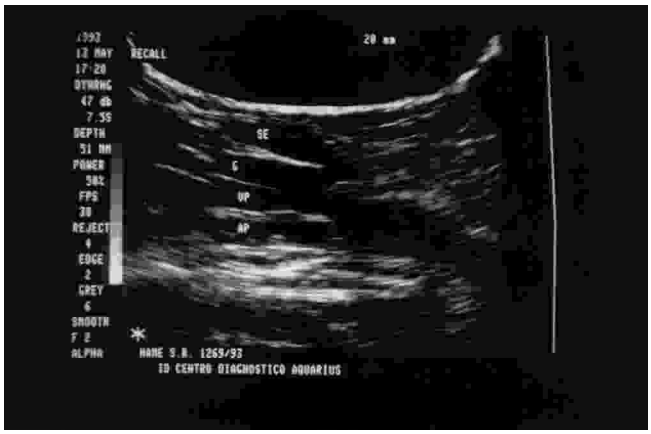


Fig. 18. - Popliteal artery (ap) and vein (vp), twin vein (G) and external Saphenous vein (se) in longitudinal section. Rare image, almost technical acrobatics, as it is difficulty to visualize all the vessels all in the same ecographic plane.

mal value ranging from 0.55 to 0.75:

$$I.R. = (A - D) / A = 1 - D/A,$$

A low I.R. is often due to intracerebral shunts. I.R. is negatively related to the heart rate[18, 19] and its value can be normalised, so to obtain the standard resistance index (I.R./Heart Rate):

$$<< I.R./Heart\ Rate>> = I.R. + 0.003(Heart\ Rate - 60) - 0.01$$

while a personalised normal index can be so computed (ideal normal value for a single individual):

$$I.R._{pers} = 0.90 - 0.003(Heart\ Rate)$$

For instance, if the heart rate is 100, the personalised normal index is 0.60.
A physiological and intuitive explanation can be given to understand this heart rate related behaviour of I.R..
In bradycardia ventricular refilling and systolic stroke increase, while the carotid flow falls during the diastole. In tachycardia, instead, carotid diastolic flow is high and systolic stroke is less important. In these cases I.R. changes are due to systemic but not to cerebral causes.
Also with a normal I.R., there could be a significant difference between the two common carotid arteries. A measure of variance and its stratification for sources of error[17] showed that standard deviation $s_d$ of several signal acquisitions was almost 0.037. For I.R. difference this value must be multiplied by square root of 2, i.e. 1.41, and taking into account the two tails distribution threshold value 1.96, the final result is:

$$\Delta I.R. > 1.96 * 1.41 * s_d = 2.76*0.037 = 0.102$$

i.e. the difference is significant when it exceeds 10 percent points.
If instead one computes the mean value of N acquisitions in each side (N.B. changing the side at each acquisition to get indipendent samples), one can reduce the threshold value, dividing it by the square root of N, because the mean standard deviation must be used.

$$\Delta I.R. > 2.76 * s_{mean} = 2.76*0.037/sqrt(N)$$

Practically, if N is set to 3 the difference between the means must not exceed 6 percent points.

$$\Delta I.R. > 2.76 * s_{mean} = 0.06$$

Other indexes can be computed from FFT of Doppler signal. I will only cite Peak, Mode, Mean, and Percent Window. Gosling Index (G.I.) is computed from FFT frequencies this way:

$$G.I. = Peak\text{-}to\text{-}Peak/Mean$$

Spectral Impedance Index (I.I) [1,2] is quite similar:

$$I.I. = (1 - Vmean/Vmax)*100$$

The greater is the difference between mean and maximum velocities, the greater is I.I., i.e. the vascular pulsatility. Multiplying it by the pressure (max, mean and min) you

can get the Static Pressure Index (S.P.I.),[1,2] which expresses the part of the pressure which has not been converted into kinetic energy.
Other indexes are also more complex, involving extensive computations, i.e. Laplace transform or Transfer Functions coefficients, and requiring special instruments.

## Abdominal and Lower Limbs Vessels

The aorta is observable in its sub-diaphragm segment, with variable results, according to abdomen volume, to its liquid/gaseous content and to the preparation of the patient to the examination.

The celiac trunk is visible near the pancreas, with its bifurcation into hepatic and splenic artery. (Fig. 13) The left gastric artery is instead hardly visible.

The location of the renal arteries and of their pathology is useful also to differentiate the aneurysms of the abdominal aorta including the aforesaid arteries, owing to the well known surgical problems. (Infrarenal and below the renal arteries aneurysms)

The aortic-iliac bifurcation allows also the observation of the possible crushing of the common left iliac vein by the common right iliac artery, achieving the so-called Syndrome of Cockett. (low nutcracker of Coolsaet) (Fig. 14)

The femoral tripod is observed prevalently in oblique section, parallel to the inguinal ligament, to visualise the bifurcation into superficial and deep femoral arteries (Fig. 15) and the generally more caudal positioned analogous venous confluence.

A high diastolic speed on the common femoral signals an obstruction or an upstream narrow stenosis and the presence of a compensating vessel in which the direction is reversed. I.e., obstruction of the common iliac homolateral artery and compensation by the reversed hypogastric. [12,13]

A brief muscular exercise, increasing the blood speed by effort hyperaemia, could render turbulent the circulatory regimen in presence of a stenosis which would not be evident while resting.

The obstruction of the superficial femoral artery is signalled by the missing downstream pulsatility and the upstream water hammer movement. (Fig. 16) Color-Doppler shows that the colour is absent, while P.W. Doppler is not generally reliable (aliasing) to differentiate narrow stenoses from obstructions.

Popliteal vessels are generally easily visible owing to their superficial position in the popliteal hollow, between the femoral condyles covered by the cartilages. (Fig. 17) However, a less visible segment there is by the point of the passage from the Hunter channel to the popliteal hollow.

It is in this zone that popliteal or Baker Cysts could be visualised.

Dacron Bypass can be easily distinguished from PTFE or other material ones by the visibility of the mesh of the wall.

The proximity allows the observation of other vessel structures as the popliteal vein and the arc of the external saphena. (Fig. 18)

The bifurcation of the popliteal into anterior tibial and tibial-peroneal trunk is visible sometimes in several images that require an extreme operator skilfulness.

The anterior tibial artery emerging in the point where it steps over the inter-osseous membrane is instead commonly observed. The visualisation of the tibial-peroneal bifurcation is instead difficult.

As an example of the previously described vascular indexes, it is to be noted that in normal subjects, the Index of Spectral Impedance on the posterior tibial artery does not change after having raised the limb or after venous occlusion, while it recuced noticeably after reactive hyperaemia or pharmacological nitro-glycerine test. Instead in arteriopathic patients in the lower limbs a clear increase after venous occlusion is observed, while the values are restored to the basic standard levels after reactive hyperaemia. [1,2]

*The Winsor Index (I.W.)* - I.W. = posterior tibial Systolic Pressure/ Omeral Arterial Pressure is always greater than the unity in the normal subjects, while it reduced in the arteriopatic patient. The segmental pressure gradient, i.e. from the thigh to the calf or from the calf to the ankle, is significant for a circulatory obstacle when it is greater than 30 mmHg.

## Conclusions

Echotomographic and Doppler examination of the arterial circulation provides essential information for the anatomical and functional evaluation, which is necessary for the medical and surgical therapy of the arteriopathies. Nevertheless, it requires a notable skilfulness. Therefore, ecographic operators should spend a period of theoretical and practical learning, and of assisted diagnostic and reporting experience, before they can be considered completely reliable.

Only in this way can echography reduce the dependence of its results on the operator skilfulness and can compete with other more standard imaging methods.

A further advantage of the ecotomography is the possibility to perform many times the same observation at close intervals and in different conditions, so pointing the real time behaviour of observed structures.

Improved clinical knowledge could therefore better orientate the operator while performing particular diagnostics manoeuvres during the examination (breath and decubitus changes, compressions, reactive and effort hyperaemia, $O_2$ or $CO_2$ inhalation, raising the arts, venous occlusion, pharmacological test).

This makes that echographic observation are closely linked to clinical work and in real terms it has to be said that vascular ecography should always be performed by operators with specific knowledge in the field of the peripheral vasculopathies.

## References


1. Bracale GC, Passariello F, Amato B, Bernardo B. Microsignal: una nuova apparecchiatura per l' analisi in linea del segnale doppler. Ultrasonografia. Quaderni di Aggiornamento. Ottobre 1986.
2. Bracale GC, Passariello F, Amato B, Carbone R, Bernardo B. Comportamento degli indici emodinamici calcolati con apparecchiatura Microsignal in soggetti normali e arteriopatici. Ultrasonografia. Quaderni di Aggiornamento. Febbraio 1987.
3. Caiazzo P. L'Insufficienza Cerebro-Vascolare, Giuseppe Piccolo Editore.
4. Carbone R,Caiazzo P, Passariello F, Sannino E. The Echography in the Supraortic Vessel Surgery. In Passariello, F. (a cura di): L'Encefalo Ben Temperato. Edises, Napoli, 1997
5. Dauzat M. Pratique de l'ultrasonographie vasculaire (Doppler-Echographie). Vigot, Paris, 1986.
6. Di Pasquale G, Vinelli S, Biancolli S, Pancaldi GL, Pozzati A, Ottani F, Urbinati S, Pinelli G. Ruolo dell'Ecocardiografia TransEsofagea nei Pazienti con Stroke, Atti Stroke 97, Montecatini 1997.
7. European Carotid Surgery Trial. Lancet, V 345, pp 209-212, January 28, 1995.
8. Franceschi C. L'investigation vasculaire par ultrasonographie Doppler. Masson Editeur, Paris, 1977
9. Franceschi C. Exploration Doppler des voies de suppléance des artères cervico-cérébrales. Journal des Maladies Vasculaires. 1981,6, 89-100.
10. Franceschi C. Manuale delle compressioni per lo studio della circolazione cerebrale e periferica con metodica ultrasonografica Doppler. Fardis ed., 1981.
11. Franceschi C, Vadrot M, Luizy F, Jardin M, Ribadeau-Dumas C, Franco G, Bouzac H. Echotomographic anatomy of the supra aortic arterial truncs. Ultrasons, 1981, 2, n. 1, 57-61.
12. Franceschi C. Esame ultrasonoro dei rami dell' aorta addominale con ecotomografia associata a doppler continuo. Quaderni di Ultrasonografia, n 1, Fardis ed., Febbraio 1982.
13. Franceschi C, Franco G, Luizy F, Tanitte M. Precis d'Echotomographie Vasculaire. Vigot, Paris, 1986.
14. International School of Ultrasonology. Neurosonology, including Doppler Ultrasound. Directors: E. Borgatti, C. Alvisi. "Ettore Majorana". Centre for Scientific Culture, Erice, March 1983.
15. International school of cerebral blood circulation Directors: C Alvisi, G Mchedlishvili . "Ettore Majorana" Centre for Scientific Culture, Erice, april 1990.
16. North American Symptomatic Carotid Endarterectomy Trial Collaborators (1991) Beneficial effect of carotid endarterectomy in symptomatic patients with high grade stenosis. N Engl J Med 325:445-452.
17. Passariello F. L' importanza delle fonti di errore nella definizione dei parametri quantitativi con C.W. Doppler e Analisi Spettrale: L' Indice di Resistenza, Atti VIII Congresso Nazionale S.I.S.U.M., Bologna 1983.
18. Passariello F. Indici velocimetrici standard del distretto cervico-encefalico. Considerazioni preliminari e metodo. Atti delle Riunioni Fiorentine di Aggiornamento in Angiologia, 5-9 giugno 1984.
19. Passariello F. Doppler cerebro-vascular indexes versys systemic hemodynamic parameters: a correlation analysis. J.E.M.U., 1985, 6, nº 6, 308-311.
20. Passariello F. Collateral Circulation and C.W.Doppler Diagnostics.Ophtalmic test Rivisited. In Passariello F. (a cura di): L'Encefalo Ben Temperato. Edises, Napoli, 1997
21. Pourcelot L. L'examen Doppler des vaisseaux périphériques. ACD Productions, Paris, 1982.
22. Rizzatto G, Solbiati L. Anatomia Ecografica, Ed. Masson.