

# VENOUS VALVULAR RECONSTRUCTION IN POST-THROMBOTIC SYNDROME

## A new technique

O. MALETI

Dipartimento di Cardiologia Medico-Chirurgica e Chirurgia Toraco-Vascolare, Hesperia Hospital, Via Arquà, 80/A  
Modena, Italia.

### ABSTRACT :

#### **Venous valvular reconstruction in post-thrombotic syndrome. A new technique.**

Patients affected by post-thrombotic syndrome at clinical stage C6 CEAP present invalidating symptomatology often not controllable with conservative therapies.

Deep vein valves reconstruction enables the patient to achieve clinical benefit. Femoral transposition and venous segment transplantation are not feasible in all situations, due to anatomical and technical limitations. These reasons have led different authors to develop techniques of valvular reconstruction.

We have applied a new valvular reconstruction technique in the case of 7 patients on whom it was not possible to perform a conventional operation.

Outcome evaluation needs a long term follow-up but good preliminary results suggest continuing with this technique. (J Mal Vasc 2002; 27: 218-221)

*Key-words :* Venous valve. Deep venous insufficiency. Venous surgery.

### RÉSUMÉ :

#### **Reconstruction veineuse valvulaire : une nouvelle technique pour le syndrome post-thrombotique.**

Les patients atteints d'un syndrome post-thrombotique au stade clinique C6 CEAP présentent une symptomatologie invalidante ne répondant pas aux thérapies conservatrices.

La reconstruction des valvules veineuses permet une amélioration clinique importante. Les contraintes anatomiques et techniques ne permettent pas la transposition fémorale et la transplantation du segment veineux dans tous les cas.

Plusieurs auteurs proposent la reconstruction valvulaire comme une alternative.

Nous avons appliqué une nouvelle technique de reconstruction valvulaire chez 7 patients pour lesquels une intervention conservatrice n'était pas possible.

L'évaluation des résultats à long terme n'est pas actuellement disponible, mais les résultats préliminaires sont encourageants. (J Mal Vasc 2002 ; 27 : 218-221)

*Mots-clés :* Valvule veineuse. Insuffisance veineuse profonde. Chirurgie veineuse.

## INTRODUCTION

Deep venous reflux may cause chronic venous insufficiency, which is often not controllable with pharmacological and compression therapies. Significant symptoms, the occurrence of trophic lesions and frequent recurrent deep thrombosis, inevitably lead to a deterioration of the patient's quality of life and impair his ability to work. The consequent working hours lost have a high social cost (1). The venous hypertension in the limbs and the impossibility of decreasing pressure values by getting the patient to walk cause altered hemodynamic homeostasis and the consequent symptomatology. Recovery of valvular function consents a normalization of pressure status and allows the hemodynamic equilibrium of the limb to be totally or

partially restored (2-5). This event results in an immediate or long-term improvement in the efficiency of associated surgical therapeutic procedures for the superficial venous system or perforating veins also conservative medical treatment (6).

A post-thrombotic reflux syndrome cannot always be corrected by the presently applied techniques and this led the authors to look for alternative solutions (7-20).

## MATERIAL AND METHODS

The preoperative study includes a Duplex scan, air plethysmography, ascending and descending phlebography (21, 22). The selection standards are the same as those applied to patients enrolled for valvular transposition and transplantation. Inclusion criteria were deep venous insufficiency CEAP: C<sub>6-S</sub> E<sub>S</sub> A<sub>D(F, P)</sub> P<sub>R(F, P)</sub> with an ulcer that had not healed after more than 5 years. Exclusion criteria were insufficiency of venous muscular pump (23) and thrombosis due to congenital coagulation disorders. In fact, new valves were created in cases in which it was technically impossible to proceed with one of the above operations. All

Reçu le 17 juin 2002.

Acceptation par le comité de Rédaction le 15 juillet 2002.

*Tirés à part :* O. MALETI, à l'adresse ci-dessus.

patients were informed about this surgical possibility and gave their informed consent in writing. The patient is normally under conditions of subarachnoid or epidural anesthesia during the operation and antibiotic prophylaxis is short-term. The limb must be in a state of equilibrium, ie be free of edemas at the time of surgery. This should be achieved by compression therapy and/or manual lymph-drainage. Before the intervention a short-elongation bandage is applied, extending from the foot to the knee.

#### SURGICAL TECHNIQUE

The technique consist in the creation of a valvular cusp by dissection of the femoral venous wall to obtain a single or bicuspid valve. The first one appears to be easier to obtain and is of equal hemodynamic efficiency. The dissection is facilitated by the post-thrombotic wall thickness (24, 25). The patient position is clinostatic and the limb slightly abducted to expose the crural area. An incision that is 10/15 cm long is made along the line of the cutaneous projection of the superficial femoral artery.

The superficial femoral artery is reached vertically, great care being taken to spare the deep lymphatic collectors. The common femoral vein is carefully isolated at its point of bifurcation; the superficial femoral vein and profunda femoral vein are also exposed to obtain complete and safe control of the whole area (*fig. 1*). The venous segment identified as the valvular reconstruction site is carefully liberated by accurate dissection of the adventitial layer. 150 UI/kg sodium heparin is administered intravenously and will not be neutralized at the end of surgical procedure. Light coated clamps are positioned and a longitudinal phlebotomy is performed to obtain a panoramic view of the inner venous wall (*fig. 2*). A blade is then used to perform parietal dissection to create a cusp which is derived by the union of the two dissection lines: transversal and longitudinal (*fig. 3*). The free edge must be as long as half the circumference of the vein and must run for 1 cm downwards like the body of a cone. The free edge of the cusp thereby obtained is fixed distally (*fig. 4*) and the same suture will close the phlebotomy (*fig. 5*). At the end of suture it is easy to evaluate valve continence. The vacuum drainage is inserted before anatomic closure. Microsurgical instrumentation and surgical glasses must be used. The use of intermittent pneumatic compression or compression stocking is recommended.

At the end of surgical procedure a bandage is applied from the foot to the thigh, with an adequate being applied to the middle of the thigh. Vacuum drainage is maintained until the fourth post-operative day to avoid lymphorrhea and lymphocele, which are two of the most annoying complications of this procedure and which delay healing and also cause long-standing medial inflammation of the thigh. It is recommended that the patient should walk on the second post-operative day but active mobilization of the limb is carried out on the first post-operative day. Sodium heparin is administered intravenously for two days and is subsequently substituted by oral anticoagulant therapy (INR range 2/3). This therapy is usually carried on for about 6 months.

#### RESULTS

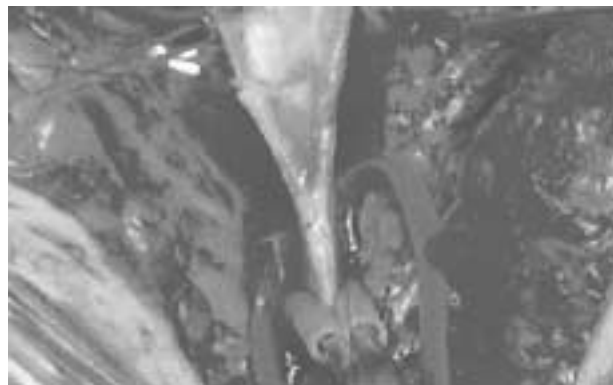
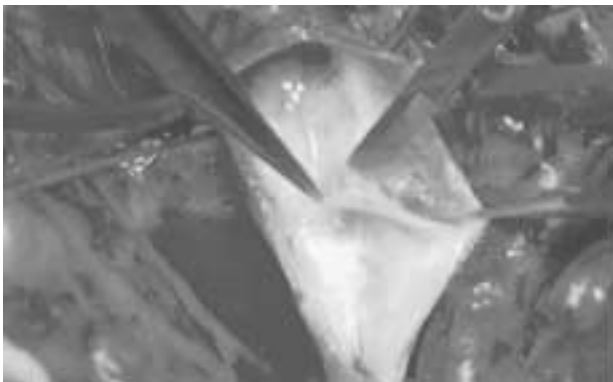
This surgical technique was used on seven patients (3 females, 4 males, age min 42 max 76, average 58.6) with a follow-up period ranging between 1 to 14 months (average 7.9). Postoperative (descending) venography was per-

formed in all cases (1 month after surgical procedure); thrombosis had not occurred and venous competence was noted in all patients. Trophic lesions that had resisted common therapeutic procedures for more than 5 years healed within 4 to 23 weeks (average 11). The reflux registered at the popliteal level by a duplex scan was less than 1 sec in 6 patients, while only 1 patient presented a reflux of 2.5 sec (which was in any case less than the pre-operative value of 4.5 sec). All preoperative reflux values were more than 4 sec. Trophic lesions also healed. An air-plethysmography post-operative evaluation showed VFI values ranging between 1.8 and 4.3 (average 2.9) in 6 patients. The patient showing a higher VFI value (4.3) had popliteal reflux during the 2.5-sec Duplex scan due to parallel reflux.

#### DISCUSSION

The technical aspects of deep vein valve reconstruction of primitive venous valve insufficiency differ from secondary or post-thrombotic deep vein valve reconstruction (26-29). In fact in cases of primitive venous valve insufficiency valvular cusp reconstruction is possible when they are present and prolapsed (30-34) but this is not feasible in post-thrombotic situations due to the valvular disruption caused by the thrombotic process. Femoral transposition and valvulated venous segment transplantation (35) are the surgical techniques normally performed in cases of post-thrombotic syndrome. They are not always feasible due to technical difficulties (transposition), valve incontinence or incongruent size (transplantation) (36, 37). For these reasons, different authors have been motivated to develop different valvular reconstruction techniques. Post-thrombotic syndrome causes venous wall damage with these typical features: wall and valvular edge thickening, partial and total destruction of the valvular apparatus. This evidence and on the anatomical detection of wall thickening have led us to develop a new valvular reconstruction technique. Accuracy in patient selection is a fundamental step towards achieving a good outcome. Age does not represent a limit but the patient's ability to perform normal physical activities is very important.

Follow-up is still insufficient to validate this new technique but the absence of venous segment thrombosis, the most feared complication, should be noted. In four cases, the endothelium side was placed facing the venous lumen and in three cases facing the valvular pocket: no thrombosis was detected in either solution. In only one case was a bicuspid valve created (last case with a one month follow-up); in all other cases a single cusp was created. In the patient with the post-operative reflux of 2.5 sec the descending venography showed a parallel reflux through the deep femoral vein with valve continence of the superficial femoral. This raises the question of whether to apply this technique, when possible, in the popliteal vein to avoid failures due to parallel reflux (36).



1	2
3	4
5	

FIG. 1. – Common femoral vein, superficial femoral vein and profunda femoral vein exposed to obtain a complete and safe control of the area.  
*Exposition de la veine fémorale commune, de la veine fémorale superficielle et de la veine fémorale profonde.*

FIG. 2. – Longitudinal phlebotomy and exposure of the inner venous wall.  
*Phlébotomie longitudinale et exposition de la paroi veineuse interne.*

FIG. 3. – Parietal dissection.  
*Dissection de la paroi.*

FIG. 4. – The cusp is fixed to the vein wall.  
*Fixation de la valvule à la paroi veineuse.*

FIG. 5. – The same suture will close the phlebotomy.  
*La fermeture de la phlébotomie se fait avec la même suture.*

## CONCLUSION

This techniques enables valve continence to be restored in many cases, although the short follow-up does not allow us to validate its long-term effectiveness.

Dedicated to Michel Perrin and Vanio Vannini. My thanks also go to Marzia Lugli.

## RÉFÉRENCES

1. RAJU S. Venous insufficiency of the lower limb and stasis ulceration. Changing concepts and management. *Ann Surg*, 1983; 197: 688-97.
2. GOOLEY N, SUMMER DS. Relationship of venous reflux to the site of venous valvular incompetence: implications for venous reconstructive surgery. *J vasc Surg*, 1988 ; 7 : 50-9.
3. RAJU S, FREDERICKS R. Valve reconstruction procedures for non obstructive venous insufficiency: rational techniques, and results in 107 procedures with 2 to 8 years follow-up. *J Vasc Surg*, 1988 ; 7 : 301-10.
4. SOTTIURAI VS. Surgical correction of recurrent venous ulcer. *J Cardiovasc Surg*, 1991 ; 32 : 104-8.
5. CHEATLE TR, PERRIN M. Surgical options in the post thrombotic syndrome. *Phlebology*, 1993 ; 8 : 50-7.
6. O'DONNELL TF, BURNARD KG, BROWSE NL. Is interruption of incompetent perforating veins really important to the management of chronic venous insufficiency? *Surgery*, 1977 ; 76 : 174-8.
7. RAI DB, LERNER MD. Chronic venous insufficiency disease. Its aetiology. A new technique for vein valve transplantation. *Int Surg*, 1982 ; 144 : 221-4.
8. JONES JW, ELLIOT F, KERSTAIN MD. Triangular venous valvuloplasty. A new procedure for correction of venous incompetence. *Arch Surg*, 1982 ; 117 : 1250-1.
9. PSATHAKIS ND. The substitute "valve" operation by technique II in patients with post-thrombotic syndrome. *Surgery*, 1984 ; 95 : 542-8.
10. WARMENHOVEN PG, KLOPPER PJ, KEEMAN JW. Construction of valves in the venous system. A preliminary report of an experimental study in dogs. *Eur Surg Res*, 1985 ; 17 : 105.
11. ZHANG BG, XU JB, ZHANG JW. Treatment of femoral venous valvular incompetence by encircling suturing of venous wall. *Zhonghua Wai Ke Za Zhi*, 1986 ; 4 : 600-3, 638.
12. JESSUP G, LANE RJ. Repair of incompetent venous valve: a new technique. *J Vasc Surg*, 1988 ; 8 : 569-75.
13. TAHERI SA, RIGAN D, WELS P *et al*. Experimental prosthetic vein valve. *Am J Surg*, 1988 ; 156 : 111-4.
14. TAHERI SA, SHORES R. Successful use of suturless prosthetic vein valve in dog. Proc 10 Congrès Mondial Union Internationale de Phlébologie. *J Lilly ed. Strasbourg*, 1989, 1035-7.
15. VAN DEN BROEK TA. Experimental surgery of the venous valves. *Phlebologie*, 1991 ; 44 : 169-71.
16. DUTANGO E. Creation of new venous valves. Presented at Second Meeting of Cardiovascular Surgeons and First Ecuadorian Cours on Angiology and Vascular Surgery. Quito Ecuador, April 1993.
17. DALSING MC, SAWCHUCK AP, LALKA SG, CIKRIT DF. An early experience with endovascular venous valve transplantation. *J Vasc Surg*, 1996 ; 24 : 903-5.
18. PLUGNOL P, CIOSTEK P, GRIMAUD JP, PROKOPOWICZ SC. Auto-genous valve reconstruction technique for post-thrombotic reflux. *Ann Vasc Surg*, 1999 ; 13 : 339-42.
19. VILLIMOUR B, GIARDULLI O, SESSA C *et al*. Fate of competence of the valvular apparatus of the femoral veins after cryopreservation. Preliminary study. *J Mal Vasc*, 1999 ; 24 : 126-31.
20. AKESSON H, RISBERG B, BJORGELL O. External support valvuloplasty in the treatment of chronic deep venous incompetence of the leg. *Int Angiol*, 1999 ; 18 : 233-8.
21. NEGLÈN P, RAJU S. A rational approach to detection of significant reflux with duplex Doppler scanning and air plethysmography. *J Vasc Surg*, 1993 ; 17 : 590-5.
22. VAN BEMMELEN PS, BEDFORD G, BEACH K, STRANDNESS DE. Quantitative segmental evaluation of venous valvular reflux with duplex ultrasound scanning. *J Vasc Surg*, 1989 ; 10 : 425-31.
23. RAJU S, FREDERICKS P, NEGLÈN P, MORANO J. Observation on the calf venous pump mechanism: determinants of post-exercise pressure. *J Vasc Surg*, 1993 ; 17 : 459-69.
24. BARRELLIER MT. Les lésions valvulaires post-thrombotiques. *J Mal Vasc*, 1997 ; 22 : 117-21.
25. MOORE DJ, HIMMEL PD, SUMNER DS. Distribution of venous valvular incompetence in patients with post-phlebotic syndrome. *J Vasc Surg*, 1986 ; 3 : 49-57.
26. MERCIER F, NUSSAUME O, GOUNY P. Traitement chirurgical des reflux de la voie veineuse profonde: technique, indications et résultats. *J Mal Vasc*, 1994 ; 19 : 175-84.
27. IAFRATI M, O'DONNELL TF. Surgical reconstruction for deep venous insufficiency. *J Mal Vasc*, 1997 ; 22 : 193-7.
28. PERRIN M. Reconstructive surgery for deep venous reflux: a report on 144 cases. *Cardiovasc Surg*, 2000 ; 8 : 246-55.
29. RAJU S, JAMES DH. Technical options in Venous Valve Reconstruction. *Am J Surg*, 1997 ; 173 : 301-7.
30. KISTNER RL, SPARKUHL MD. Surgery in the acute and chronic venous disease. *Surgery*, 1979 ; 85 : 31.
31. KISTNER RL. Primary venous valve incompetence of the leg. *Am J Surg*, 1980 ; 140 : 218-24.
32. GLOVICZKI P, MERSELL SW, BOWER TC. Femoral vein valve repair under direct vision without veinotomy: a modified technique with use of angioscope. *J Vasc Surg*, 1991 ; 5 : 645-8.
33. SOTTIURAI VS. Technique in direct venous valvuloplasty. *J Vasc Surg*, 1988 ; 8 : 646-8.
34. KISTNER RL. Surgical repair of venous valve. *Straub Clinic Proc*, 1968 ; 34 : 41-3.
35. TAHERI SA, LAZAR L, ELIAS S *et al*. Surgical treatment of postphlebotic syndrome with vein valve transplant. *Am J Surg*, 1982 ; 144: 221-4.
36. BRY JD, MUTO PA, O'DONNELL TF, ISAACSON LA. The clinical and hemodynamic results after axillary-to-popliteal vein valve transplantation. *J Vasc Surg*, 1995 ; 21 : 110-9.
37. TAHERI SA, ELIAS SM, YACOBUCCI GN *et al*. Indication and results of vein valve transplant. *J Cardiovasc Surg*, 1986 ; 27 : 163-8.
38. ERIKSSON I, ALMEGREEN B. Influence of the profunda femoris vein and venous hemodynamics of the limb. *J Vasc surg*, 1986 ; 4 : 390-5.